



Intravitreal bevacizumab injection alone or combined with macular photocoagulation compared to macular photocoagulation as primary treatment of diabetic macular edema

Intravitrealna primena bevacizumaba sa ili bez laser-tretmana u poređenju sa laser-tretmanom kao primarnim načinom lečenja dijabetesnog edema makule

Sandra Jovanović*, Vladimir Čanadanović*, Ana Sabo†, Zorka Grgić*,
Milena Mitrović‡, Dušan Rakić§

*Clinic for Eye Diseases, †Endocrinology, Diabetes and Metabolic Disorders Clinic, Clinical Center of Vojvodina, Faculty of Medicine, University of Novi Sad, Novi Sad, Serbia; ‡Department of Pharmacology, Toxicology and Clinical Pharmacology, Faculty of Medicine, University of Novi Sad, Novi Sad, Serbia; §Department of Mathematics, Faculty of Technology, University of Novi Sad, Novi Sad, Serbia

Abstract

Background/Aim. Within diabetic retinopathy (DR), diabetic macular edema (DME) is one of the leading causes of the loss of visual acuity. The aim of this study was to determine the efficacy of the intravitreal vascular endothelial growth factor (VEGF) inhibitor application alone or combined with macular focal/grid laser photocoagulation compared with laser treatment alone. **Methods.** This prospective randomized clinical trial included 72 patients (120 treated eyes) with varying degrees of DR and DME. The DME treatment included intravitreal VEGF inhibitor bevacizumab (Avastin®) application, with and without laser treatment. Bevacizumab (1.25 mg/0.05 mL) was administered intravitreally in 4–6-week intervals. Laser is applied 4–6 weeks after last dose of the drug as a part of combined treatment, or as the primary treatment. **Results.** The mean reduction in central macular thickness (CMT) for the eyes ($n = 31$) treated with bevacizumab alone was 162.23 μm , for the eyes ($n = 53$) treated with combined treatment the

mean reduction in CMT was 124.24 μm , both statistically significant at $p < 0.001$. Laser macular photocoagulation as a part of combined treatment (in 53 eyes) significantly contributed to the CMT reduction, based on the paired t -test results (366.28 vs 323.0 μm at $p < 0.05$). In our study, the mean visual acuity improvement of 0.161 logMAR was achieved in the group of eyes treated with bevacizumab alone, and 0.093 logMAR in the group with combined treatment, both statistically significant at $p < 0.05$. The effect of laser photocoagulation alone on visual acuity and CMT was not statistically significant. **Conclusion.** Treatment with bevacizumab alone or within combined treatment is more effective in treating DME than conventional macular laser treatment alone, both anatomically and functionally.

Key words:

diabetic retinopathy; macular edema; ophthalmologic surgical procedures; vascular endothelial growth factors; light coagulation; treatment outcome.

Apstrakt

Uvod/Cilj. U sklopu dijabetesne retinopatije (DR) jedan od najranijih razloga koji dovodi do pada oštine vida je dijabetesni makularni edem (DME). Cilj rada bio je utvrđivanje efikasnosti lečenja DME intravitrealnom primenom inhibitora vaskularnog endotelnog faktora rasta (VEGF) samostalno ili u sklopu kombinovanog lečenja laserfotokoagulacijom makule tipa fokal/grid i poređenje sa konvencionalnim lečenjem makule laserom. **Metode.** Istraživanje je sprovedeno kao prospektivna, randomizirana klinička studija na 72 bolesnika (120 lečena oka) sa različitim stepenom DR i DME. Lečenje DME podrazumevalo je intravitrealnu primenu inhibitora VEGF bevacizumaba (Avastin®) sa ili bez

primene lasera. Lek je primenjivan u dozi 1,25 mg u 0,05 mL u razmacima od 4 do 6 nedelja. Laserfotokoagulacija vršena je u kontrolnoj grupi kao primarni vid terapije ili kao dopuna prethodnog lečenja makule aplikacijom bevacizumaba nakon 4–6 nedelja od poslednje doze ukoliko nije došlo do poboljšanja centralne debljine makule (CMT). **Rezultati.** Prosečna vrednost smanjenja CMT za oči ($n = 31$) lečene samo bevacizumabom iznosila je 162,23 μm , za oči lečene kombinovanom metodom ($n = 53$) redukcija CMT iznosila je 124,24 μm ; statistički značajno u obe grupe $p < 0,05$. Laserfotokoagulacija makule kod bolesnika/očiju sa kombinovanim lečenjem statistički značajno je doprinosila dodatnom redukovanju CMT na osnovu uporednog t -testa (366,28 prema 323,0 μm ; $p < 0,05$). U našoj studiji postignuto

prosečno poboljšanje oštine vida u grupi očiju lečenih intravitrealnom primenom bevacizumaba iznosilo je 0,161 logMAR, kod očiju sa kombinovanim lečenjem, 0,093 logMAR, statistički značajno u obe grupe $p < 0,05$. Uticaj laserfotokoagulacije, samostalno, na oštrinu vida i CMT bio je bez statističke značajnosti. **Zaključak.** Lečenje DME intravitrealnim aplikacijama bevacizumaba samostalno ili u sklopu kombino-

vanog lečenja je efikasnije nego konvencionalno lečenje makule laserom, kako anatomske tako i funkcionalno.

Ključne reči: dijabetesna retinopatija; žuta mrlja, edem; hirurgija, oftalmološka, procedure; faktori rasta endotela krvnih sudova; fotokoagulacija; lečenje, ishod.

Introduction

Diabetic retinopathy (DR), a microangiopathic complication of diabetes mellitus (DM), is among the leading causes of acquired blindness in developed countries (in patients aged 65 or older), as well as developing countries (in working-age population, aged 45 to 65)¹. Thus, DR is not only medical, but also socioeconomic issue. DR is one of the most frequent DM complications, occurring in 40% of affected individuals above the age of 40².

Within DR, diabetic macular edema (DME) is one of the earliest causes of the loss of visual acuity. The development of DME is typically noted in older patients diagnosed with Type II DM³. DME prevalence of approximately 14% has been reported in DM affected individuals⁴. While DME onset can occur at any stage of DR development, it is more frequent in more severe DR forms, and its prevalence increases with the illness duration. The type of DM, as well as therapy (insulin, orally administered hypoglycemic agents, or diet), is also noteworthy. In addition to the aforementioned factors, further contributors to DR and DME onset and progression are metabolic glycemic control, arterial hypertension, dyslipidemia and proteinuria⁵.

In the DME pathophysiology, chronic hyperglycemia plays the key role, causing oxidative stress and retinal capillary endothelial cell damage accompanied by inflammatory response, the consequence of the breakdown of hemato-retinal (H-R) barrier⁶. The disruption of the flow control mechanisms leads to hypoxia, causing the release of vascular endothelial growth factor (VEGF).

VEGF plays an important role in the early phases of DR development, as the decomposition of the "tight junctions" leads to the breakdown of the inner H-R barrier, which results in increased permeability and development of DME⁷. On the other hand, in the hypoxia conditions, VEGF represents the most potent mitogen for the vascular endothelial cells, as it induces the angiogenesis process. VEGF-A is most frequently encountered in ocular pathology, and is the target of most anti-VEGF agents^{8,9}. Application of anti-VEGF agents has led to significant improvements in the treatment of vascular-ischemic ophthalmic diseases.

Bevacizumab (Avastin[®]; Genentech, San Francisco, USA) provides recombinant humanized monoclonal IgG1 antibodies in their entirety, aimed against all VEGF-A isoforms. In 2004 bevacizumab was approved by the Food and Drug Administration for intravenous infusion application, as a part of chemotherapy in the treatment of metastatic carcinoma of the colon and the rectum. Off-label bevacizumab application in ophthalmology in the form of intravitreal in-

jections was first introduced as a part of the treatment of age-related macular degeneration – the wet form. The application scope subsequently widened to include DME, following the favorable results reported in the DR clinical research network studies¹⁰.

In treating DME, in addition to the necessary management of the primary condition and other risk factors, thus far, laser photocoagulation used to be a gold standard. However, numerous studies have demonstrated that laser treatment can only stabilize the current state¹¹. Recently, new promising treatment forms have emerged, including the aforementioned medications in the VEGF inhibitor group.

The aim of this study was to evaluate the efficacy of DME treatment consisting of intravitreal VEGF inhibitor application alone or as a part of combined treatment (intravitreal VEGF inhibitor plus laserphotocoagulation) compared with laser treatment alone.

Methods

The research was conducted as a prospective randomized clinical study at the Clinic for Eye Diseases, Clinical Center of Vojvodina, in Novi Sad during a 2012–2013 period. The study was approved by the Clinical Center of Vojvodina Ethics Committee. The participating patients provided their informed consent, after being provided written and verbal information on the application of off-label medications and their potential side-effects. The study included 72 patients (120 treated eyes) with varying degrees of DR and DME. DR and DME were defined according to the International Clinical Diabetic Retinopathy and Diabetic Macular Edema Disease Severity Scale, published by the International Council of Ophthalmology (ICO) in 2002¹².

The treatment consisted of intravitreal VEGF inhibitor bevacizumab (Avastin[®]) application, with and without laser treatment. In the control group the patients were treated with laserphotocoagulation only. The patients that met the following criteria were included in the study: severe DME that affects the fovea, reduction in visual acuity and/or metamorphopsia, diffuse edema with or without cystic edema [confirmed by fluorescein angiography (FA) and by optical coherence tomography (OCT)], central macular thickness (CMT) $\geq 300 \mu\text{m}$, the absence of hard lipid exudates in the form of plaque in the subfoveal region, no prior laser treatment, no prior VEGF inhibitor treatment, and no previous intravitreal or subtenonian corticosteroid administration. The exclusion criteria were: high risk and advanced proliferative DR (PDR), the presence of other eye diseases that could affect visual acuity, prior eye surgeries, recent myocardial in-

fraction, insult, and unregulated DM (Hb1c higher than 11%) and hypertension.

All the participating patients were given full ophthalmological examination, which included determining the best corrected visual acuity (BCVA), intraocular pressure (IOP) measurement, examination of the anterior eye segment, examination of the posterior segment in medical mydriasis *via* contactless ophthalmoscopy using the 90 D magnifying glass (by Volk). The auxiliary diagnostic procedures performed included FA and OCT. FA was initially performed with the aim of diagnosing the edema type, and was repeated upon the treatment completion (both pharmacological and laser components). OCT was instrumental in assessing the patients for inclusion in the study, as well as in the monitoring of treatment efficacy. It was performed on the apparatus manufactured by Carl Zeiss Meditec, Dublin, CA, "Stratus" model, using the "fast macula" or "fast macula thickness map" program.

Intravitreal application of 1.25 mg bevacizumab (0.05 mL of Avastin[®]) was performed under surgical microscope at 4 mm distance from limbus, in the *pars plana* region of the ciliary body, using a 27 G diameter syringe. Avastin[®] was administered in the operating theatre in strict sterile conditions.

Control follow-ups were performed four weeks after the treatment, and included BCVA determination, fundus examination in mydriasis, and OCT. Visual acuity was converted into the logarithm of the Minimal Angle of Resolution (logMAR). If required, the treatment was repeated 4 to 6 weeks after the initial application, and at two further occasions at the same intervals. Once the pharmacological treatment was completed, due to satisfying results or no further improvement, next step of treatment, laserphotocoagulation using the focal/grid method, was performed after 4 to 6 weeks. The effect of combined therapy was evaluated after 6 weeks. The aim was to achieve the CMT below 250 μm , *ie*, as close to normal values as feasible.

All statistical analyses were performed using the software package Statistica (version 10). The mean values of the

obtained results were analyzed *via* paired *t*-test at 95% confidence interval. This approach was most suitable for this study, as the values obtained for each patient were compared individually, at different treatment stages.

Results

The study included 72 patients (120 treated eyes), all of whom had complete data and were followed-up for a minimum of six months. The average age of patients diagnosed with DR and DME was 62.5, ranging from 25 to 78 years.

The mean duration of DM and insulin therapy was 14.7 and 7.2 years, respectively. Among the participating patients, the greatest number (61%) suffered from Type II DM, all of whom were secondarily insulin dependent. The mean glycaemia level among the participating patients was 8.85 mmol/L, for adult with DM, the target level is between 4 and 7 mmol/L while HbA1c was 7.7% (it is recommended to be as close to normal as possible < 6%).

Among the 72 study participants, 3% of patients were diagnosed with mild non proliferative DR (NPDR), 46% with moderate NPDR form, 44% had severe NPDR form and 7% low risk PDR. The patients with both high risk and advanced PDR were excluded from the study, as the six-month follow-up was not feasible due to the need to perform laser intervention (panretinal laser photocoagulation), which is known to affect the DME.

One injection of bevacizumab application was required to achieve adequate CMT in 12 eyes (14%), two doses were required in 28 eyes (34%), while in most cases (37, or 44%), three doses were required. Finally, in 7 eyes (8%), four Avastin[®] doses were necessary before satisfactory CMT values were obtained and better conditions for subsequent laser-photocoagulation treatment achieved.

Figure 1 shows macular optical coherence tomography in the patient with DME, before and after the treatment with a single dose of Avastin[®].

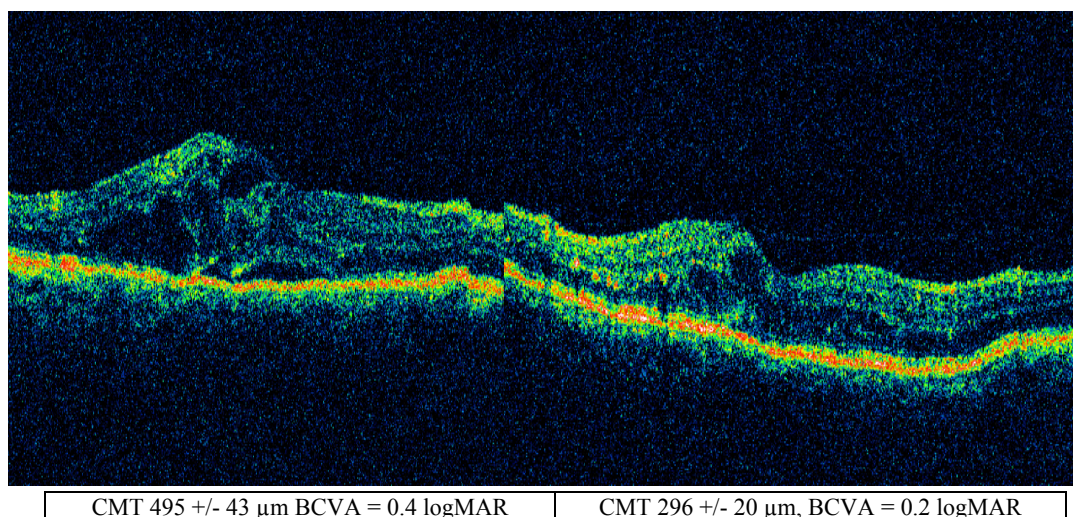


Fig. 1 – Macular optical coherence tomography of an eye before the treatment with a single anti-vascular endothelial growth factor therapy, bevacizumab (Avastin[®]), and four weeks after the treatment.
CMT – central macula thickness; BCVA – best corrected visual activity; MAR – minimum angle of resolution.

The data presented in Table 1 indicates the manner in which the patients ($n = 51$ patients, 84 eyes) were grouped according to the number of doses received. It is evident that the number of administered doses is directly proportional to the increasing CMT values, indicating that progressively more severe forms of edema required longer treatment and a greater number of doses. In the first group of eyes requiring a single dose, edema was least pronounced, and the initial and the final mean CMT values were $348 \mu\text{m}$ and $220.5 \mu\text{m}$, respectively, corresponding to $127.5 \mu\text{m}$, or 36.6%, reduction. In 9 of 12 eyes, the CMT declined below the $250 \mu\text{m}$ threshold (representing the normal value). In the group of eyes that required two Avastin[®] doses, the initial and the final mean CMT values were $411.6 \mu\text{m}$ and $255.6 \mu\text{m}$, respectively, corresponding to the $156 \mu\text{m}$, or 37.9%, reduction. In addition, in 17 of the 28 eyes, the CMT declined below the $250 \mu\text{m}$ threshold. In the group requiring three Avastin[®] doses, at $508.4 \mu\text{m}$, the initial mean CMT value was greater than in the previous two groups, declining to $381.6 \mu\text{m}$ post-treatment, thus achieving the CMT reduction of $126.8 \mu\text{m}$, *ie*, 29.4%. A reduction to the thickness below $250 \mu\text{m}$ was achieved in 7 of 37 eyes. In the fourth group of eyes that required four applications of medication, the initial mean CMT was the highest, $525.5 \mu\text{m}$, and declined to $379.1 \mu\text{m}$ upon treatment completion. The achieved CMT reduction of $146.4 \mu\text{m}$ corresponded to 27.8%, with only one case reaching the normal thickness of $250 \mu\text{m}$. The data presented in Table 2 indicate that each post-treatment CMT value is statistically

significantly different from the initial one ($p < 0.05$).

Once the pharmacological treatment was completed, due to satisfying results or no further improvement, the next step of treatment, laser photocoagulation using the focal/grid method on 53 eyes, was performed after 4 to 6 weeks. The effect of combined therapy was evaluated after 6 weeks.

The mean reduction in CMT for the eyes ($n = 31$) treated with bevacizumab alone was $162.23 \mu\text{m}$, for the eyes ($n = 53$) treated with combined treatment the mean reduction in CMT was $124.24 \mu\text{m}$ which was achieved with 2.4 doses on the average in the bevacizumab group and 2.5 doses in the bevacizumab plus laser group. The difference between the initial and the final mean CMT values in both patient groups are statistically significant at $p < 0.001$ (Table 3). The difference between the final values of achieved CMT comparing the groups bevacizumab *vs* bevacizumab plus macular laser is not significant ($p = 0.52$). In the control group, the eyes treated with laserphotocoagulation alone ($n = 36$) reduction in CMT was $6.88 \mu\text{m}$, which was not statistically significant.

The mean visual acuity improvement of $0.161 \log\text{MAR}$ was achieved in the group of eyes treated with bevacizumab alone, $0.093 \log\text{MAR}$ in the eyes treated with combined treatment. The difference between the initial and the final mean logMAR values in both patient groups was statistically significant at $p < 0.05$. On the other hand, there was no statistical difference between final visual acuity comparing groups bevacizumab *vs* bevacizumab plus macular laser $p = 0.81$ (Table 3).

Table 1

Doses (n)	CMT (μm)		Improvement		Treated eyes	Below	Below
	Initial	Final	Absolute (μm)	Relative (%)	(n)	$250 \mu\text{m}$ (n)	$300 \mu\text{m}$ (n)
1	347.92	220.58	127.33	36.60	12	9	11
2	411.68	255.64	156.03	37.90	28	17	23
3	508.38	381.57	126.81	24.94	37	7	8
4	525.57	379.14	146.43	27.86	7	1	2

Table 2

Paired *t*-test of initial and final central macula thickness (CMT) values by the groups (based on the number of administered doses)

CMT vs OCT	$\bar{x} \pm \text{SD}$	<i>t</i> -test	<i>t</i>	df	Final value
CMT 0	347.9167 ± 90.86499	CMT vs CMT 1	5.743785	11	2.2281388
CMT 1	220.5833 ± 52.80575				
CMT 0	411.6786 ± 89.51807	CMT vs CMT 2	7.278081	27	2.0555294
CMT 2	255.6429 ± 76.98254				
CMT 0	508.3784 ± 159.2392	CMT vs CMT 3	4.757189	36	2.0301079
CMT 3	381.5676 ± 122.7714				
CMT 0	525.5714 ± 77.0127	CMT vs CMT 4	2.391307	6	2.5705818
CMT 4	379.1429 ± 138.9561				

OCT – optical coherence tomography; \bar{x} – mean value; SD – standard deviation; df – degrees of freedom.

Table 3

Paired *t*-test of visual acuity (VA) and central macula thickness (CMT) before (1) and after (2) the treatment with bevacizumab (– b) *vs* bevacizumab plus macular laserphotocoagulation (b+lfc) and laser group only (lfc)

Treatment	n	VA, mean \pm SD (LogMAR)	<i>p</i>	CMT, mean \pm SD (μm)	<i>p</i>
b+lfc 1	53	0.484 ± 0.322	0.0019	447.245 ± 121.059	< 0.0001
b+lfc 2		0.388 ± 0.393		323.000 ± 134.114	
b 1	31	0.572 ± 0.432	< 0.0001	467.323 ± 164.934	< 0.0001
b 2		0.409 ± 0.398		305.097 ± 100.963	
lfc 1	36	0.429 ± 0.349	0.0114	347.177 ± 101.428	0.4604
lfc 2		0.474 ± 0.360		340.294 ± 101.966	

SD – standard deviation.

Following the macular laser photocoagulation as the first treatment, visual acuity worsened, 0.046 logMAR, with statistical significance ($p < 0.05$).

The results presented in Table 4 indicate that the additional CMT reduction achieved through macular laser photocoagulation, as a part of the combined treatment, was statistically significant, as confirmed by the paired t -test (366.28 μm vs 323.0 μm) at $p < 0.05$. There is no improvement in visual acuity in the group with combined treatment after additional laserphotocoagulation ($p > 0.05$).

In order to determine if the degree of DR had influence on severity of DME and treatment response, the patients (treated eyes) were grouped into groups – mild to moderate NPDR and severe NPDR with low risk PDR, as presented in Table 5. CMT was improved by 117.25 μm in the group of eyes with mild to moderate NPDR (34 eyes treated with bevacizumab), and the group with severe NPDR to low risk PDR average improvement was 152.54 μm . In both groups this difference was statistically significant ($p < 0.001$). The difference between the two final mean values of achieved CMT comparing the two groups was not statistically significant (326.059 \pm 50.618 μm vs 309.820 \pm 37.420 μm ; $p = 0.55$).

Visual acuity improved 0.168 logMAR in the first group compared to 0.089 logMAR in the second. This improvement was also significant in the first and the second group ($p < 0.0001$, and $p < 0.005$, respectively) (Table 5). The difference between this two mean values of final visual acuity comparing the two groups was not significant (0.318 \pm

0.290 logMAR vs 0.448 \pm 0.444 logMAR, $p = 0.14$). In the group of eyes ($n = 36$) treated with laser there was no statistically significant improvement, nor in the mild to moderate, neither in the severe and low risk PDR group.

A low value ($r = 0.036$) of Pearson's correlation coefficient between HbA1c and the difference of OCT value before and after anti-VEGF treatment indicates no significant relation between them.

Discussion

Our study was prospective, randomized, clinical study, designed to evaluate and compare effectiveness of pharmacological treatment with anti-VEGF therapy (bevacizumab – Avastin[®]) alone and combined treatment with anti-VEGF (bevacizumab – Avastin[®]) plus macular laserphotocoagulation in relation to macular laserphotocoagulation like conventional therapy only. A total of 72 patients were examined, 120 eyes treated, and the minimum follow-up period was 6 months. Some of the previous studies had similar design. For example, in a study of Iranian authors¹³, the follow-up was at 6 months; 40 patients – 80 eyes were examined, each patient underwent intravitreal bevacizumab treatment in one eye and in the second one intravitreal bevacizumab at the same time as macular laser treatment. In that way the systemic conditions are the same in the experimental and the control group, which is preferable but we did not have this possibility during our research. The BOLT study had a much

Table 4

Paired t -test of visual acuity (VA) and central macula thickness (CMT) values of eyes treated by bevacizumab before (1) and after (2) additional laser treatment (focal/grid)

Treatment	n	VA, mean \pm SD (LogMAR)	p	CMT, mean \pm SD (μm)	p
b+lfc 1	53	0.376 \pm 0.346	0.631200	366.28 \pm 117.2	0.006
b+lfc 2		0.388 \pm 0.393		323.00 \pm 134.114	

b + lfc – bevacizumab + laserphotocoagulation; SD – standard deviation; OCT – optical coherence tomography.

Table 5

Paired t -test of visual acuity (VA) and central macula thickness (CMT) before (1) and after (2) the treatment in the group of mild to moderate nonproliferative diabetic retinopathy (NPDR) compared to the severe NPDR-low risk proliferative diabetic retinopathy [treated with bevacizumab only and in combined therapy (b) vs macular laserphotocoagulation (lfc)]

Treatment	n	VA, mean \pm SD (logMAR)	p	CMT, mean \pm SD (μm)	p
b1 mod	34	0.486 \pm 0.292	< 0.0001	443.323 \pm 49.500	< 0.0001
b2 mod		0.318 \pm 0.290		326.059 \pm 50.618	
b1 sev	50	0.537 \pm 0.411	0.0033	462.360 \pm 36.020	< 0.0001
b2 sev		0.448 \pm 0.444		309.820 \pm 37.420	
lfc1 mod	18	0.396 \pm 0.360	0.1213	362.250 \pm 107.086	0.1604
lfc2 mod		0.447 \pm 0.396		340.250 \pm 111.550	
lfc 1 sev	18	0.462 \pm 0.345	0.0033	333.778 \pm 97.201	0.5486
lfc 2 sev		0.501 \pm 0.330		340.333 \pm 95.933	

SD – standard deviation; mod – moderate; sev - severe.

longer follow-up period – up to two years¹⁴. A total of 80 patients were examined with center involving CSME. One group of eyes underwent injections of bevacizumab at baseline, at 6, and at 12 weeks. The patients were examined every 6 weeks and the treatment was stopped if CMT was stable (3 consecutive visits and CMT within 20 μm of the thinnest recorded CMT), while we considered that the treatment was finalized when there was no change in OCT at the two latest visits. A Diabetic Retinopathy Clinical Research Network (DRCR) study was also designed to compare the effect of two different doses of bevacizumab alone and in combined treatment¹⁰. Haritoglou et al¹⁵, Kook et al.¹⁶, and Mehta et al.¹⁷, in their studies, assessed patients with resistant DME who were previously unsuccessfully treated by macular focal laser, panretinal laserphotocoagulation, pars plana vitrectomy with internal limiting membrane peeling, and intravitreal triamcinolone. These authors reported that bevacizumab therapy could yield greater improvements in refractory edema in comparison to other therapy modes. This model is different to our study model, because we included new cases without any treatment before.

The data presented in Table 1 indicate that the first and the second group included patients with quantitatively less severe edema; thus, the treatment could be achieved through fewer Avastin[®] doses, but was also more effective. The third and the fourth group in particular, included cases of more severe edema, which required greater number of Avastin[®] doses, yet failed to achieve efficacy noted in the first two groups. The mean CMT reduction in all the treated eyes was 139.15 μm (31.81%), which was achieved with 2.46 doses, on the average. In 34 of the 84 (40.47%) eyes subjected to treatment, edema reduction $\leq 250 \mu\text{m}$ was achieved. It is evident that the number of administered doses is directly proportional to the increasing CMT values, indicating that progressively more severe forms of edema required longer treatment and a greater number of doses.

Intravitreal injections of bevacizumab administration was at 4–6 weeks interval, until satisfying results were obtained. If there was no further improvement, the next step of treatment was performed – focal/grid laserphotocoagulation mostly at 4–6 weeks after the last intravitreal application. In the study conducted by Roh et al.¹⁸, the author investigated the duration of the period after which edema reoccurred unless anti-VEGF therapy was repeated. In 24 patients (31 eyes) from that study, edema reoccurred 12 weeks after the initial treatment, unless a new dose was administered. A conclusion was that next doses should be administered until edema reoccurred. In a Pan-American study on 16 eyes (20.5%) second injection was administered, on the average 13.8 weeks apart (4–28 weeks); 6 eyes (7.7%) received third injection on the average interval 11.5 weeks (5–20 weeks). This type of administration at the time when edema reoccurs is not recommended¹⁹. Most of the authors like Scott et al.¹⁰, Haritoglou et al.¹⁵, Kook et al.¹⁶, Mehta et al.¹⁷ and Kumar and Sinha²⁰ choose administration with 6 weeks apart.

The mean reduction in CMT in our study for the eyes ($n = 31$) treated with bevacizumab alone was 162.23 μm , for the eyes ($n = 53$) treated with combined treatment it was

124.24 μm which was achieved with 2.4 doses on the average in the bevacizumab group and 2.5 doses in the bevacizumab plus laser group. The difference between the initial and the final mean CMT values in each patient group was statistically significant at $p < 0.001$. In the control group, eyes treated with laserphotocoagulation alone ($n = 36$), a reduction in CMT was 6.88 μm , which was not statistically significant. In the Iranian study a reduction in CMT in the first group of eyes intravitreal bevacizumab (IVB) was 40 \pm 38 μm and in the second one [IVB+ macular photocoagulation (MPC)] 43 \pm 13 μm , the results were achieved with 2.23 injections in first group (IVB) and 2.49 injections in the second group (IVB+MPC). Edemas in the Iranian study were very mild compared to our study, the CMT at baseline for the IVB group was 261 \pm 115 μm and for the IVB plus MPC group 270 \pm 93 μm ¹³. In our study baseline CMT was much higher – 467.323 μm in the group of eyes treated with bevacizumab only, 447.245 μm in the group of eyes treated with combined therapy, which could explain a better response to the treatment.

The mean reduction in CMT in the bevacizumab group was 146 μm and 118 μm in the macular laserphotocoagulation (MLC) group in the BOLT study¹⁴, achieved with 13 injections (9 in the first and 4 in the second year), and 4 macular laser treatment (3 in the first and 1 in the second year). In the Kumar and Sinha²⁰ study the treatment efficacy of 120 μm achieved through two doses 6 weeks apart at 6 months analyses; Haritoglou et al.¹⁵, Kook et al.¹⁶ and Mehta et al.¹⁷ reported the improvement in CMT from 106–124 μm , and Arevalo et al.¹⁹ in the Pan-American study 111 μm . We obtained similar results concerning CMT reduction (13915 μm) using 2.46 doses on the average.

In our study, the mean visual acuity improvement of 0.161 logMAR was achieved in the group of eyes treated with bevacizumab alone, 0.093 logMAR in the eyes treated with combined treatment. The difference between the initial and the final mean logMAR values in each patient group was statistically significant at $p < 0.05$ Following the macular laser photocoagulation as a first treatment, visual acuity worsened 0.046 logMAR with a statistical significance ($p < 0.05$). In the Iranian study¹³ BCVA was improved in the first group (0.138 logMAR), and 0.179 logMAR in the second, which is very similar to our results. Haritoglou et al.¹⁵, Kook et al.¹⁶ and Mehta et al.¹⁷ in their studies which analyzed treatment of edema have results from 0.05 to 0.11 logMAR. Their results are slightly lower than ours, probably because they included patients with persistent, chronic edema.

In our study, the mean CMT improved more in the group of eyes treated with bevacizumab only compared to the eyes with combined treatment. Focusing on the group of eyes with combined therapy, laser has been done 6 weeks apart of the last injection, and CMT significantly improved due to laser treatment (363.3 vs 323.0 μm) $p < 0.05$. Many studies showed that there is no difference between bevacizumab group only and bevacizumab plus macular laser therapy. In the Iranian study¹³, the authors conclude at the end of treatment that there are no differences between the group of eyes treated with bevacizumab and the group of eyes treated with bevacizumab plus macular laser. They consider application of laser 2–3 weeks after the anti-

VEGF treatment in order to have better consolidative effect. In our study, laser is applied 4–6 weeks apart from the last injection, with a significant improvement of CMT and no improvement in visual acuity. Korean authors²¹ applied laser 4 weeks after the last injection. Combined therapy in DRCR did not achieve a significantly greater improvement compared to the treatments based on bevacizumab alone⁹.

In order to determine if the degree of DR has influence on severity of DME and treatment response, patients (treated eyes) were grouped into groups – mild to moderate NPDR and severe NPDR with low risk PDR, as presented in Table 5. In both groups improvement of CMT was on statistical level of 99%, in visual acuity improvement was on the statistical level of 99% on moderate, 95% significance for severe NPDR and low risk PDR. In the laser group there was no improvement, visual acuity was worsened in the group with severe NPDR-low risk PDR. In the Pan-American study¹⁹, ANOVA analysis could not find a statistically significant difference in the reduction of edema

in eyes with NPDR and PDR (panretinal laserphotocoagulation is performed at least 6 months before).

A low value ($r = 0.036$) of Pearson's correlation coefficient between HbA_{1c} and the difference of OCT value before and after anti-VEGF treatment indicate no significant relation between them.

In a study of Korean authors²¹, they tried to make a correlation between the reduction of macular edema and the type of edema (diffuse, cystoid, edema with serous retinal detachment and mixed edema). This could be a very good approach for the next phase of our research.

Conclusion

The treatment with bevacizumab alone or combined treatment (consisting of bevacizumab administration and macular laserphotocoagulation) are more effective in treating diabetic macular edema than conventional macular laser treatment alone, both anatomically and functionally.

R E F E R E N C E S

1. Klein R. Retinopathy in a population-based study. *Trans Am Ophthalmol Soc* 1992; 90: 561–94.
2. Kempner JH, O'Colmain BJ, Leske MC, Haffner SM, Klein R, Moss SE, et al. The prevalence of diabetic retinopathy among adults in the United States. *Arch Ophthalmol*. 2004; 122(4): 552–63.
3. Orchard TJ, Dorman JS, Maser RE, Becker DJ, Drash AL, Ellis D, et al. Prevalence of complications in IDDM by sex and duration. *Pittsburgh Epidemiology of Diabetes Complications Study II*. *Diabetes* 1990; 39(9): 1116–24.
4. Girach A, Lund-Andersen H. Diabetic macular oedema: a clinical overview. *Int J Clin Pract* 2007; 61(1): 88–97.
5. Williams R, Airey M, Baxter H, Forrester J, Kennedy-Martin T, Girach A. Epidemiology of diabetic retinopathy and macular oedema: a systematic review. *Eye* 2004; 18(10): 963–83.
6. Gardner TW, Antonetti DA, Barber AJ, LaNoue KF, Levison SW. Diabetic retinopathy: more than meets the eye. *Surv Ophthalmol* 2002; 47(Suppl 2): S253–62.
7. Cai J, Boulton M. The pathogenesis of diabetic retinopathy: old concepts and new questions. *Eye (Lond)* 2002; 16(3): 242–60.
8. Ferrara N. Role of vascular endothelial growth factor in physiologic and pathologic angiogenesis: therapeutic implications. *Semin Oncol* 2002; 29(6 Suppl 16): 10–4.
9. Takahashi H, Shibuya M. The vascular endothelial growth factor (VEGF)/VEGF receptor system and its role under physiological and pathological conditions. *Clin Sci* 2005; 109(3): 227–41.
10. Scott IU, Edwards AR, Beck RW, Bressler NM, Chan CK, Elman MJ, et al. A phase II randomized clinical trial of intravitreal bevacizumab for diabetic macular edema. *Ophthalmology* 2007; 114(10): 1860–7.
11. Fong DS, Strauber SF, Aiello LP, Beck RW, Callanan DG, Danis RP, et al. Writing Committee for the Diabetic Retinopathy Clinical Research Network. Comparison of the modified Early Treatment Diabetic Retinopathy Study and mild macular grid laser photocoagulation strategies for diabetic macular edema. *Arch Ophthalmol* 2007; 125(4): 469–80.
12. Wilkinson CP, Ferris FL, Klein RE, Lee PP, Agardh CD, Davis M, et al. Proposed international clinical diabetic retinopathy and diabetic macular edema disease severity scales. *Ophthalmology* 2003; 110(9): 1677–82.
13. Faghghi H, Esfahani MR, Harandi ZA, Madani SH. Intravitreal bevacizumab vs. combination of intravitreal bevacizumab plus macular photocoagulation in clinically significant diabetic macular edema: 6 months results of a randomized clinical trial. *Iranian J Ophthalmol* 2010; 22(1): 21–6.
14. Rajendram R, Fraser-Bell S, Kaines A, Michaelides M, Hamilton RD, Esposti SD, et al. A 2-year prospective randomized controlled trial of intravitreal bevacizumab or laser therapy (BOLT) in the management of diabetic macular edema: 24-month data: report 3. *Arch Ophthalmol* 2012; 130(8): 972–9.
15. Haritoglou C, Kook D, Neubauer A, Wolf A, Priglinger S, Strauss R, et al. Intravitreal bevacizumab (Avastin) therapy for persistent diffuse diabetic macular edema. *Retina* 2006; 26(9): 999–1005.
16. Kook D, Wolf A, Kreutzer T, Neubauer A, Strauss R, Ulbig M, et al. Long-term effect of intravitreal bevacizumab (avastin) in patients with chronic diffuse diabetic macular edema. *Retina* 2008; 28(8): 1053–60.
17. Mehta S, Blinder KJ, Shah GK, Kymes SM, Schlieff SL, Grand MG. Intravitreal bevacizumab for the treatment of refractory diabetic macular edema. *Ophthalmic Surg Lasers Imaging* 2010; 41(3): 323–9.
18. Rob MI, Byeon SH, Kwon OW. Repeated intravitreal injection of bevacizumab for clinically significant diabetic macular edema. *Retina* 2008; 28(9): 1314–8.
19. Arevalo J, Fromow-Guerra J, Quiroz-Mercado H, Sanchez JG, Wu L, Maia M, et al. Primary intravitreal bevacizumab (Avastin) for diabetic macular edema: results from the Pan-American Collaborative Retina Study Group at 6-month follow-up. *Ophthalmology* 2007; 114(4): 743–50.
20. Kumar A, Sinha S. Intravitreal bevacizumab (Avastin) treatment of diffuse diabetic macular edema in an Indian population. *Indian J Ophthalmol* 2007; 55(6): 451–5.
21. Lee SJ, Kim ET, Moon SY. Intravitreal bevacizumab alone versus combined with macular photocoagulation in diabetic macular edema. *Korean J Ophthalmol* 2011; 25(5): 299–304.

Received on April 2, 2014.

Revised on September 5, 2014.

Accepted on September 15, 2014.

Online First August, 2015.